

**AL FARABI KAZAKH NATIONAL UNIVERSITY**  
**Medicine and Health Care Faculty**  
**Higher School of Medicine**  
**Department of Fundamental medicine**

**Final exam program of**  
**OACH1201 "The Human Body (Medical terminology include)"**  
**(4 credits)**

Topics for the final exam:

**1. Tissue of Human body I-II**

Human tissue. The main classes of classification of adult tissue. Germ layers of human tissues. The structure and location of epithelial tissue, connective tissue, muscle tissue, nervous tissue. Epithelial tissue, connective tissue, muscle tissue, nerve tissue, three germinal germ layers. Three-dimensional shape of the structure, two-dimensional section of the tissue

**2. Tissue of Human body III**

Epithelial tissue. Types of epithelium, their differences from each other. The structure of the epidermis, dermis and subcutaneous tissue. Types of sweat glands, sebaceous and ceruminous glands, their structure. Skin functions. Histology of the hair and its follicle. Hair types. The most common forms of skin cancer.

**3. Medical terminology. Organization of the body I.**

The Language of Medicine. Anatomical Position. Anatomical Planes. Directional Terms. Major Body Regions (Axial and Appendicular Region). Body Cavities and Membranes. Organ Systems.

**4. Organization of the body II. The integumentary system I-II**

The Scope of Anatomy Physiology. Human Structure. Human Function. Structure and functions of the skin. Dermal circulation. Structure and functions of the Cutaneous Glands. Skin Disorders

**5. Medical imaging I-II**

X-ray imaging. Positron Emission Tomography. Computed Tomography. Magnetic Resonance Imaging. Ultrasonography

**6. Human Tissue IV-V**

Connective Tissue. Tissues and Organs of the Skeletal System. Histology of Osseous Tissue

**7. The skeletal system I-III**

Bone Development. Physiology of Osseous Tissue. Bone Disorders

**8. The skeletal system IV**

Cranial Bones. Facial Bones

**9. The skeletal system V**

General Features of the Vertebral Column. General Structure of a Vertebra. Intervertebral Discs. Regional Characteristics of Vertebrae. Thoracic Cage

**10. The skeletal system VI**

The Shoulder Girdle. The Upper Limb

**11. The skeletal system VII**

The Pelvic Girdle. The Lower Limb

**12. Joints and Their Classification. Anatomy and physiology of individual joints**

Recap: capstone case

## Learning outcomes

Students on the final written and test exam must demonstrate in their responses the ability to:

- 1) describe and determine the general plan of the structure of the human body; 2) describe and localize the bones of the trunk, skull and limbs, taking into account age, gender and individual characteristics;
- 3) describe and localize the joints of the bones of the body, head and extremities, their structure and movements in them, taking into account age, gender and individual characteristics;
- 4) describe and localize muscles, places of their origin and attachment, function, taking into account age, gender and individual characteristics;
- 5) find and show their anatomical structures of the musculoskeletal system in the image, dummy and preparation, medical imaging materials (taking into account age characteristics), name them, including in Latin;
- 6) find and palpate bone and muscle landmarks on a living person;
- 7) apply the basics of international medical terminology - anatomical and clinical; 8) integrate knowledge of anatomy, physiology, histology and medical biophysics to explain the main phenomena of important medical importance;
- 9) independently find, analyze and generalize educational and scientific information in relation to situations related to the content of the course;
- 10) work in a team, defend their point of view reasonably, consider the opinions of others, provide and receive feedback correctly using the skills of interpersonal and group communication

### A rough typology of tasks for the exam

To pass the exam in writing/oral.

#### **Organization of the body.**

Medical terminology. Introduction to Medical Terminology. Human Functions. Introduction to anatomy of physiology. Sphere of anatomy, physiology, human structure. Homeostasis, negative feedback, positive feedback, gradient. Anatomical position, Anatomical planes, directional terms. Main areas of the body (axial and appendicular region), body cavities and membranes, organ systems

1. *Explain why modern medical terminology is based on Greek and Latin.*
2. *Break down medical terms into their main word parts.*
3. *What are some reasons why the literary meaning of a word does not always coincide with its definition?*
4. *What are some examples of singular and plural forms of some nouns and adjectives? 5. What are the differences between the axial and appendicular regions of the body*
6. *Identify the pivot area subdivisions and landmarks that divide and define them.*
7. *Show the four quadrants and nine areas of the abdomen; their defining landmarks; and Explain why this regimen is clinically useful*
8. *Name the segments of the upper and lower extremities; how the anatomical meanings of the arm and leg differ from the spoken meanings,*
9. *Determine the locations and contents of the cranial cavity, spinal canal, chest cavity and abdominal cavity; the membranes that line them; and the main guts contained in each*
- 10.

- describe the content of the mediastinum and its relationship with the chest cavity as a whole,*
11. *give a definition of the pericardium, name its two layers, space and fluid between layers, and its function*
  12. *give a definition of pleura, Name its two layers, the space and fluid between the layers, and their functions*
  13. *Show willingness and willingness to learn, be an effective team member, and develop self-directed learning and problem-solving skills;*
  14. *Name the two divisions of the abdomen and the skeleton that separates them*
  15. *Give a definition of the peritoneum;*
  16. *What are its functions; its two layers and their connection with the abdominal cavity; and abdominal fluid, mesentery and serous membrane*
  17. *Give examples of intraperitoneal and retroperitoneal organs, and how you can identify an organ as intraperitoneal or retroperitoneal,*
  18. *Give the definition and location of the posterior and anterior mesentery, 19. describe the serous membrane of the abdominal-muscular organ and how it is connected with the peritoneum,*
  20. *Give examples of potential spaces and why they are named so*
  21. *Define anatomy, physiology and relate them to each other,*
  22. *list the levels of a person's structure from the most difficult to the simplest, 23. discuss the value of both reductionist and holistic viewpoints for understanding human form and function,*
  24. *discuss the clinical relevance of anatomical changes in humans,*
  25. *indicate the characteristics that distinguish living organisms from inanimate objects.*
  26. *Explain the importance of physiological changes in humans.*
  27. *give a definition of homeostasis*
  28. *Explain why this concept is central to physiology,*
  29. *give a definition and give an example of negative feedback,*
  30. *Explain its importance for homeostasis,*
  31. *give a definition of positive feedback and give examples of its beneficial and harmful effects,*
  32. *give definition of gradient,*
  33. *Describe the variety of gradient in human physiology and identify some forms of matter and energy that flow along the gradients*

## **Tissue of Human body.**

Skin structure and function. Epithelial tissue, connective tissue, muscle tissue, nervous tissue, three embryonic germ layers. Three-dimensional shape of the structure, two-dimensional tissue section. Hair and their follicles, nails, three classes of burns. Epithelium types. Bone system tissues. Connective tissue. Muscular connective tissues, bundles and muscle groups.

1. *Name the four main classes into which all adult tissues are classified,*
2. *What are the three germ layers and examples of some adult tissues obtained from each layer,*
3. *visualize the three-dimensional shape of the structure from a two-dimensional tissue section,*
4. *describe the structure and location of epithelial tissue, connective tissue, muscle tissue,*

*nervous tissue*

5. Name and classify the types of epithelium, distinguish them from each other, 6. describe the histological structure of the epidermis, dermis and subcutaneous tissue,
7. Name two types of sweat glands, sebaceous and ceruminous glands, and describe their structure;
8. list the functions of the skin and relate them to its structure
9. describe the histology of the hair and its follicle,
10. what are the differences between the three types of hair,
11. describe the three most common forms of skin cancer
12. Name the tissues and organs that make up the skeletal system
13. distinguish between bone as tissue and as organ
14. list and describe the cells, fibers and base material of the bone tissue
15. indicate the importance of each bone component
16. Identify and Compare the Histology of Two Types of Bone Tissue
17. Identify and compare histology of two types of bone marrow
18. Name and classify the types of connective tissue, describe their cellular components and matrix, and explain how they differ from each other
19. describe the properties that most connective tissues have
20. discuss the types of cells found in connective tissue
21. Explain what the connective tissue matrix is and describe its components 22. visually recognize each type of connective tissue from samples or photographs 23. describe the components of connective tissue in muscles and their relation to the internal organization of muscles and compartments

### **The integumentary system.**

Skin structure and function. Skin tones, general skin signs. The structure and function of the skin glands, skin blood circulation; skin cancer.

1. list the functions of the skin and relate them to its structure
2. Describe the three classes of burns and the priorities for treating burns 3. describe the normal and abnormal colors that the skin can have, explain their causes 4. describe common skin markers
5. Name two types of sweat glands, relate the structure and function of each 6. describe the location, structure and function of the sebaceous and ceruminous glands 7. describe the role of cutaneous circulation
8. list the functions of the skin and relate them to its structure
9. describe the three most common forms of skin cancer
10. Demonstrate knowledge of normal integumentary anatomy and physiology (including histology)

### **Medical imaging.**

Computed tomography, magnetic resonance imaging, ultrasonography, X-ray examination; Positron Emission Tomography

1. describe the general principle of 5 modern medical imaging techniques
2. What are 5 modern medical imaging techniques and how they are used?
3. discuss the uses and disadvantages of X-ray imaging and PET
4. discuss the conditions of use and disadvantages of CT
5. discuss the conditions of use and disadvantages of MRI
6. discuss the conditions of use and disadvantages of ultrasonic.

### **Skeletal system:**

Bone Physiology; bone disorders. Bone development, X-ray examination. Bones associated with the skull, cranial bones, facial bones. Skull in infancy and childhood. General features of the spine, general structure of the vertebra, intervertebral discs. Characteristics of the vertebrae and chest. Chest and upper limb. Upper limb. Pelvic girdle. Lower limb.

1. What are some skeletal system functions?
2. Discuss the role of bones in regulating calcium and phosphate levels in the blood
3. What are the main hormones that regulate bone physiology,
4. describe their action, describe the role of calcium in the skeletal system
5. describe two mechanisms of bone formation
6. describe the processes by which minerals are added to and removed from bone
7. Name and describe bone diseases associated with bone development
8. describe the development of the skull from infancy to childhood
9. Explain why bone count varies by age and individual
10. distinguish the bones of the facial from the bones of the cranial vault
11. Demonstrate knowledge of normal anatomy and physiology of the skeletal system (including histology)
12. describe the general characteristics of the spine and a typical vertebra; 13. describe the structure of the intervertebral discs and their connection with the vertebrae 14. identify the vertebrae in different areas of the spine
15. identify the sternum and ribs and describe how the ribs articulate with the thoracic vertebrae
16. identify and describe the features of the clavicle, scapula, humerus, radius, ulna 17. identify and describe the features of the bones of the wrist and hand
18. describe the common features of tubular bone and flat bone
19. Name and describe the types of fractures
20. Explain how the fracture is healed
21. discuss some of the clinical treatments for fractures
22. Identify and describe the features of the pelvic girdle
23. compare the anatomy of the male and female pelvic girdles and explain the functional significance of the differences
24. identify and describe features of the femur, patella, shin bones, fibula, and foot bones

### **Joints.**

Joints and their classification. Jaw joints, shoulder joints. Hip and knee joints. Elbow and ankle joints.

1. *Explain what joints are, how they are called and what functions they perform*
2. *Name and describe the four main categories of joints*
3. *Identify the anatomical components of a typical synovial joint*
4. *Identify the main anatomical features of the jaw, shoulder joints, hip and knee joints, elbow and ankle joints*
5. *Explain how the mechanical advantage relates to the strength and speed of the bones that make up these joints, the movement of these joints*
6. *Discuss the factors that determine the range of motion of these joints*
7. *Describe the main axes of rotation that the bone can have and relate this to the degree of freedom of the joint*
8. *Demonstrate an understanding of the relationship between structure and function at the level of tissue, organs and organ systems and the basic physiological mechanisms of maintaining homeostasis, vital functions of the body and their characteristics, taking into account age, sex and individual differences;*
9. *Demonstrate teamwork, self-study, and problem-solving skills;*
10. *Demonstrate knowledge of normal anatomy and physiology of the skeletal system (including histology)*

**The list of anatomical structures to be submitted to the exam.**

**Topic: Skull**

**Anatomical structures:**

1. supraorbital foramen / notch
2. supraorbital margin
3. glabella
4. sella turcica
5. optic canal
6. anterior clinoid process
7. superior orbital fissure
8. pituitary fossa
9. foramen rotundum
10. foramen ovale
11. foramen spinosum
12. foramen lacerum
13. medial pterygoid plate
14. lateral pterygoid plate
15. coronal suture
16. sagittal suture
17. parietal foramen
18. zygomatic process
19. mandibular fossa
20. mastoid process
21. mastoid notch
22. stylomastoid foramen
23. internal auditory canal

24. carotid canal
25. jugular foramen
26. foramen magnum
27. basilar part
28. occipital condyle
29. hypoglossal canal
30. condylar canal
31. external occipital protuberance
32. superior nuchal line
33. inferior nuchal line
34. orbital plate
35. superior nasal concha
36. middle nasal concha
37. crista galli
38. infraorbital foramen
39. frontal process
40. orbital surface
41. alveolar process
42. palatine process
43. maxillary sinus
44. mental tubercle
45. foramen mentale
46. condylar process
47. coronoid process
48. mandibular notch
49. mandibular foramen
50. angle of mandible
51. mandibular ramus
52. body of the hyoid bone
53. greater horn
54. lesser horn

**Topic: Shoulder girdle**

**Anatomical structures:**

1. superior margin
2. medial margin
3. lateral margin
4. inferior angle
5. superior angle
6. spine of the scapula
7. supraspinatus fossa
8. infraspinatus fossa
9. scapular notch
10. acromion
11. coracoid process
12. glenoid cavity
13. subscapular fossa

14. head of rib
15. neck of rib
16. costal tubercle
17. costal groove
18. conoid tubercle
19. sternal end
20. acromial end
21. manubrium
22. suprasternal (jugular) notch
23. clavicular notch
24. sternum body
25. sternum angle
26. xiphoid process

**Topic: Pelvic bones**

**Anatomical structures:**

1. iliac crest
2. acetabulum
3. superior anterior iliac spine
4. iliac fossa
5. inferior anterior iliac spine 6.
- superior ramus of the pubic bone 7.
- inferior branch of the pubic bone 8.
- obturator foramen
9. ischial ramus
10. ischial spine
11. large sciatic notch
12. superior posterior iliac
- spine 13. auricular surface
14. inferior posterior iliac
- spine 15. lesser ischial notch
16. ischial tuberosity

**Topic: Upper limb**

**Anatomical structures:**

1. anatomical neck
2. Greater tubercle
3. lesser tubercle
4. intertubercular sulcus
5. deltoid tuberosity
6. head of humerus
7. humerus block
8. lateral epicondyle
9. medial epicondyle
10. lateral supracondylar crest
11. medial supracondylar crest
12. olecranon fossa



13. coronary fossa
14. radial fossa
15. radial tuberosity
16. styloid process
17. elbow notch
18. radius neck
19. trochlea
20. olecranon
21. coronoid process
22. radial notch
23. styloid process
24. interosseous margin

**Topic: Lower limb**

**Anatomical structures:**

1. fossa of the head
2. greater trochanter
3. lesser trochanter
4. intertrochanteric crest
5. intertrochanteric line
6. linea aspera
7. linea pectinea
8. gluteal tuberosity
9. medial supracondylar line
10. lateral supracondylar line
11. medial epicondyle
12. lateral epicondyle
13. medial condyle
14. lateral condyle
15. intercondylar fossa
16. patellar surface
17. popliteal surface
18. lateral condyle
19. medial condyle
20. intercondylar eminence
21. tibial tuberosity
22. medial malleolus
23. head of fibula
24. apex of the fibula
25. lateral malleolus
26. scaphoid bone
27. lunate bone
28. triangular bone
29. pisiform bone
30. trapezoid bone
31. trapezium bone
32. capitate bone
33. hamate bone

34. hook of the hamate bone
35. base of the metacarpal bone
36. metacarpal head
37. proximal phalanx
38. distal phalanx
39. middle phalanx
40. calcaneus
41. talus
42. scaphoid bone
43. medial sphenoid bone
44. intermediate cuneiform bone
45. lateral cuneiform bone
46. cuboid bone

**Topic: Vertebral column**

**Anatomical structures:**

1. dens
2. foramen transversum
3. superior articular facet
4. inferior articular facet
5. spinous process
6. costal fovea of the transverse process
7. superior costal fossa
8. posterior tubercle
9. anterior tubercle
10. inferior costal fovea
11. body of the vertebra
12. anterior sacral foramen
13. median sacral crest
14. lateral sacral crest
15. posterior sacral foramen
16. auricular surface
17. promotorium
18. superior articular process
19. transverse process

**Theme: Joints**

**Anatomical structures:**

1. coracoacromial ligament
2. coracoclavicular ligament, conoid ligament
3. coracoclavicular ligament, trapezius ligament
4. acromioclavicular ligament
5. radial ligament
6. patellar ligament
7. peroneal collateral ligament
8. anterior fibular head ligament
9. anterior cruciate ligament

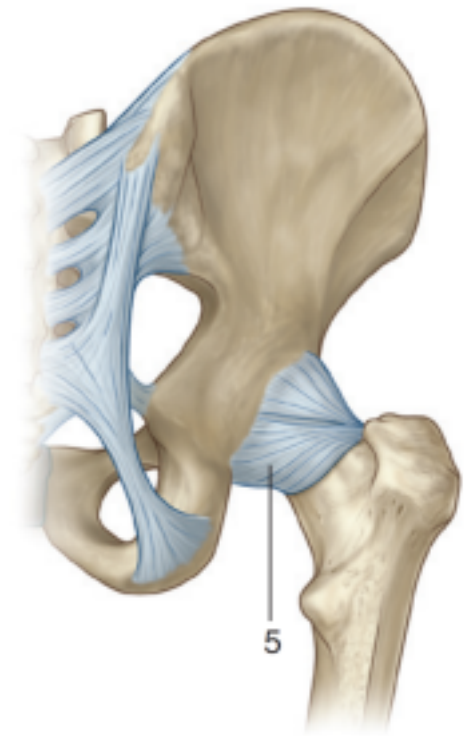
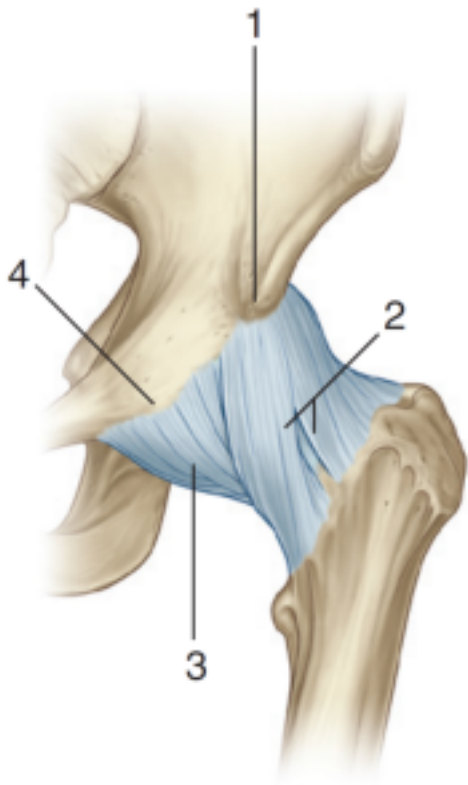
10. tibial collateral ligament
11. posterior cruciate ligament
12. transverse knee ligament
13. posterior meniscomfemoral ligament
14. sacro-tuberous ligament

### **List of histological preparations submitted for examination**

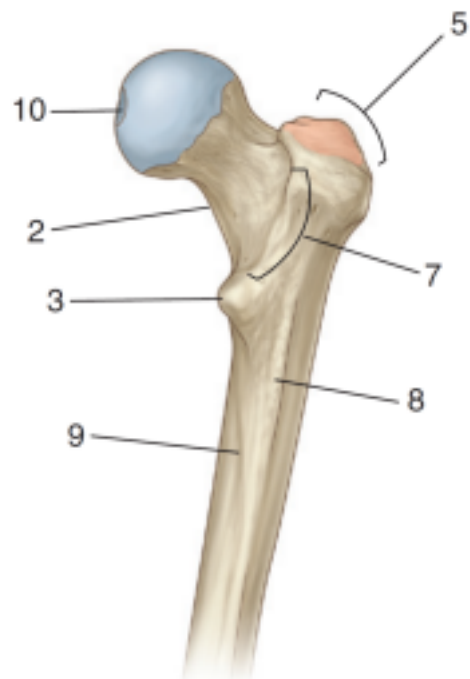
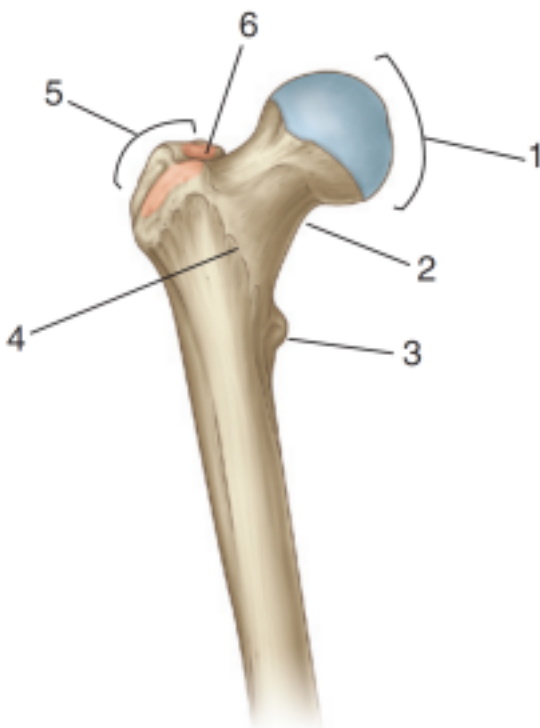
1. Low prismatic epithelium of the renal tubules. Hematoxylin-eosin
2. High prismatic epithelium of renal tubules. Hematoxylin-eosin 3.  
Multi-row ciliated epithelium; Hematoxylin-eosin
4. Stratified squamous non-keratinizing epithelium; Hematoxylin-eosin
5. Stratified squamous keratinizing epithelium; Hematoxylin-eosin 6.  
Bladder epithelium; Hematoxylin-eosin
7. Finger skin. Epidermis; Hematoxylin-eosin
8. Finger skin. Dermis; Hematoxylin-eosin
9. Skin with hair. Hair follicles. Hematoxylin-eosin
10. Skin with hair. Hair root. Hematoxylin-eosin;
11. Skin with hair. Sebaceous glands. Hair lifting muscle. Hematoxylin-eosin;
12. Skin with hair. Cross section through the hair root. Azocarmine;
13. Loose unformed connective tissue; Iron hematoxylin.
14. Loose unformed connective tissue; Macrophages. Iron hematoxylin.
15. Loose unformed connective tissue; Fibroblasts. Iron hematoxylin.
16. Dense loose fibrous connective tissue of the skin of the finger. Mallory staining;
17. Tendon longitudinal section; Hematoxylin-eosin
18. Lymph node reticular tissue. Hematoxylin-eosin
19. Hyaline cartilage. Hematoxylin-eosin;
20. Elastic cartilage. Hematoxylin - orcein;
21. Fibrous cartilage. Hematoxylin-eosin;
22. Lamellar bone tissue. Schmorl staining.
23. Mesenchymal bone development. Hematoxylin-eosin;

### **Example of anatomy assignment:**

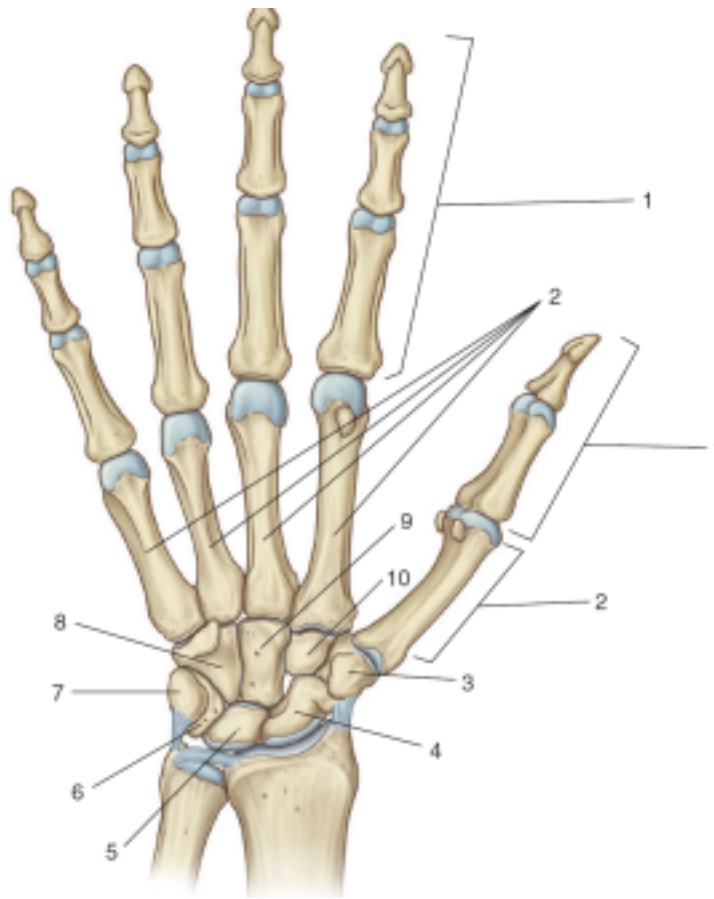
1. Name the joint, define its affiliation according to the classification of joints. Name each anatomical structure that is marked in the picture and write its function.



2. Write the name of the bone, determine if it is right or left. Identify each marked structure and write its function.



3. Write the name of the anatomical structures indicated in the picture. Write down the names of the joints that are formed by these structures and indicate their type using the synovial

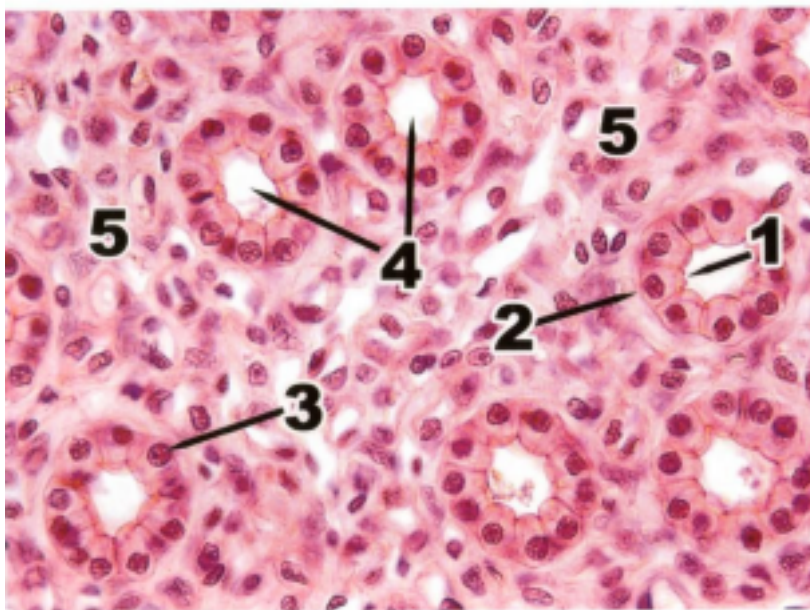


joint classification.

Example of

**histology assignment:**

Low prismatic epithelium of rabbit kidney tubules. Hematoxylin-eosin. x 400. Name the structures indicated by numbers. Describe the structure of the epithelium lining the kidney tubules. Compare the structural features of monolayer and stratified epithelium. Describe the structure of secretory cells. List the classifications of the glands.



**Response quality scale (written / oral response)**

Mark	Criteria	Scale, points
------	----------	---------------



Unsatisfactory (F)	<ol style="list-style-type: none"> <li>1. most or all of the key aspects are omitted;</li> <li>2. no focus on the question, not much related to the issue of information;</li> <li>3. significant gaps in theoretical questions, or their superficial consideration;</li> <li>3. the lack of examples or irrelevant examples; 4. there is no analysis and no theoretical justification for the given problem (if applicable), most of the key aspects are omitted;</li> <li>5. problems in using professional terminology</li> </ol>	0-24
--------------------	--	------

#### Grading system

Rating by letter system	Digital equivalent of points	Percentage	Evaluation using the traditional system
A	4,0	95-100	Excellent
A-	3,67	90-94	
B+	3,33	85-89	Good
B	3,0	80-84	
B-	2,67	75-79	
C+	2,33	70-74	Satisfactory
C	2,0	65-69	
C-	1,67	60-64	
D+	1,33	55-59	
D-	1,0	50-54	

FX F I (Incomplete)	<u>0</u> <u>0</u> -	25-49 0-24 -	Unsatisfactory  «Discipline is not completed» <i>(it is not taken into account when <u>calculating the GPA</u>)</i>
P (Pass)	-	-	«Pass» <i>(it is not taken into account when <u>calculating the GPA</u>)</i>
NP (No Pass)	-	-	«Not pass» <i>(it is not taken into account when <u>calculating the GPA</u>)</i>
W (Withdrawal)	-	-	«Withdrawal» <i>(it is not taken into account when <u>calculating the GPA</u>)</i>
AW (Academic Withdrawal)			Academic Withdrawal <i>(it is not taken into account when <u>calculating the GPA</u>)</i>
AU (Audit)	-	-	«Audit» <i>(it is not taken into account when <u>calculating the GPA</u>)</i>
Cert.		30-60 50-100	Certified
Not cert.		0-29 0-49	Not certified
R (Retake)	-	-	Repeated study of the discipline

### Exam technology instruction

1. The exam lasts exactly **3 hours**.
2. At the specified time, the student visits the "**app.oqylyq.kz**" website.
3. Student receives login and password in **IS Univer**.
4. Generation of a ticket for each student is made automatically.
5. The exam begins with obligatory proctoring (you cannot turn off the camera and microphone): - you need a laptop or home computer with a webcam. If it is not available, you can use the smartphone camera, for example, with the "DroidCam client" application.
6. The answer is printed in the field of the **OQYLYQ** program itself. A handwritten response form on a piece of paper is **NOT PROVIDED**.
7. Upon completion of the exam, the student clicks the "**Finish**" button.

### Bibliography

#### Basic literature:



1. Saladin, Kenneth S: Anatomy & Physiology. The Unity of Form and Function (2016, McGraw-Hill Education) на англ. яз.
2. Costanzo, Linda S.: BRS Physiology. Board Review Series.7 edition. -Wolters Kluwer Health, 2018.- 307p. - ISBN 1496367693, 9781496367693
3. Leslie P. Gartner: Color Atlas and Text of Histology. - 7th Edition. - Wolters Kluwer, 2017. ISBN 1496346734, 9781496346735
4. Russell K. Hobbie, Bradley J. Roth: Intermediate Physics for Medicine and Biology. - Springer, 2015. - ISBN 3319126822, 9783319126821
5. Andersson D, Medical Terminology: The Best and Most Effective Way to Memorize, Pronounce and Understand Medical Terms: Second Edition, ISBN-13 : 978-1519066626, 2016

**Additional literature:**

6. Standring, Susan: Gray's Anatomy: The Anatomical Basis of Clinical Practice. - 41 Elsevier Limited, 2016
7. Elaine N. Marieb, Lori A. Smith: Human Anatomy & Physiology Laboratory Manual, Main Version. - 11 edition. - Pearson Education,2015. - ISBN 9780133999143
8. Scanlon V. C, Essentials of Anatomy and Physiology 8th Edition, F.A. Davis Company, 2018
9. Victor P. Eroschenko, Atlas of Histology with Functional Correlations 13th Edition, LWW, 2017
10. William Bialek: Biophysics: Searching for Principles. -Princeton University Press, 2012. - ISBN 0691138915, 9780691138916

**Online resources:**

1. <https://app.lecturio.com/#/>
2. <https://3d4medical.com/>
3. [https://www.youtube.com/channel/UCc\\_I2c2bUtO0p4DVeo6-Kxg](https://www.youtube.com/channel/UCc_I2c2bUtO0p4DVeo6-Kxg)
4. <https://sites.google.com/a/umich.edu/bluelink/curricula/anatomy-403?authuser=0>
5. <https://histologyknmu.wixsite.com/info/gistologicheskie-sajty>
6. <https://histologyknmu.wixsite.com/info/gistologicheskie-sajty>
7. <http://www.histology-world.com/contents/contents.htm>
8. <http://www.histologyguide.com/slidebox/02-epithelium.html>
9. <https://histology.medicine.umich.edu/resources>
10. <https://web.duke.edu/histology/>
11. <http://virtuallslides.med.umich.edu/Histology/view.apml?listview=1&>